

Studies on Mammalian Haematozoan Parasites of NWFP Pakistan

¹Rukhsana Talat, ²Tanweer Khanum and ²Aliya Hayat

¹Department of Zoology, ²Department of Microbiology,
Jinnah University For Women, 5-C, Nazimabad, Karachi, Pakistan

Abstract: Blood smears of 424 mammals were collected from different areas of NWFP belonging to Chiroptera, Legomorpha, Rodentia, Carnivora, Ruminantia were examined. Bats were found infected with *Polychromophilus melanipherus* incidence was 31.7%. *Babesia canis* was observed in Jackal 100% *Anaplasma ovis* was found in cattle. A crithidia stage of *Trypanosoma melophagium* was recorded from sheep. Rabbits, rats, mice, guinea pigs, cat were also examined but found refractory.

Key words: *Polychromophilus melanipherus*, *Babesia canis*, *Anaplasma ovis*, *Anaplasma marginale*, *Crithidia*

INTRODUCTION

The haematozoa causes several diseases which affect the death rate of the wild life and also disturb the function of haemopoietic system of mammals. This significant work was followed by a series of reports. Olson^[1] studied the biology and life cycle of Animal parasites. Garnham^[2-5] carried out an extensive survey and discovered several instances of malarial infection among the mammals. Lapage^[6] discussed the parasites of veterinary importance. Mohiuddin^[7] studies parasitic protozoa. Admn *et al.*^[8] described the importance of Medical and veterinary protozoan. Hore^[9] reported the crithidial stage of *Trypanosoma melophagium* distributed in the Central Asia, Northern India, Japan, Australia, New Zealand, Hawaii, Europe, North and South America.

Levin^[10] discussed the protozoan parasites of domestic animals. Iliyas and Ansari^[11], Faust *et al.*^[12] gave attention on the importance of community medicine and clinical parasitology.

Haider^[13] reported the *Plasmodium* malarial infection in *Anthropithecus troglodytes* in Karachi. Haider and Bilqees^[14] studies on Plasmodium infection in some mammals in Karachi. Anderson^[15] reserach on blood parasites of mammals and discovered specie of *Hepatozoon* in New Guinea spiny bandicoot (*Echymipera kalubu*), trypanosome infection were found in three genera of rodent hosts. de Roode *et al.*^[16] and Reece *et al.*^[17] research on Rodent malaria Parasites (*Plasmodium chabaudi*). Borssy^[18], Jones *et al.*^[19,20] investigated on the malaria of penguins. Haematological survey on two species of sea Turtles in Arabian Sea were

reported by Alkindi and Mahmoud^[21]. Basham *et al.*^[22] studied the effect of thiocyanate on the blood and muscles of camels (*Camelus dromedaries*). Talat^[23] observed different species of plasmodium in birds.

The present investigation was carried out to observe the blood parasites of mammals in NWFP Pakistan.

MATERIALS AND METHODS

Blood films of 424 different mammals were collected from different areas of NWFP in June and July 2003. The blood of goats, Sheep and cattle were collected from the slaughter house while the blood of wild mice taken from the tail vein and pricking ear pinna in case of rabbits and guinae pigs.

The blood smears were made on clean sterilized slides, which were cleaned with 70% alcohol. Mostly thin blood films were made which after fixing with methyle alcohol were stained with giemsa stain (BDH) at a concentration of 2 drops of stain in one cc of buffered distilled water (pH 7.2) stained blood smears were examined under oil immersion (x100). A thorough examination of each slide was made from 20/30 fields.

The diagrams of the parasites were drawn by the help of camera lucida and the measurement of parasites infected and normal RBC were taken by ocular micrometer on a calibrated microscope.

RESULTS AND DISCUSSION

Among 424 mammals 59 i.e. 13.91% have shown the infection with haematozoa. Five species of haematozoa

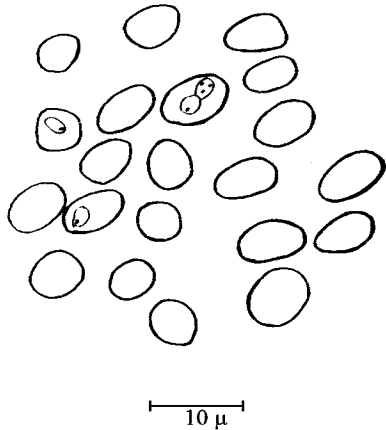


Fig. 1: *Babesia canis* (Trophozoites)




Fig. 2: *Polychromophilus melanipherus*
(a) Trophozoite (b) Gametocyte

Table 1: Incidence of infection among mammals

Mammalian host	Species of parasite	No. of positive Total No. of samples	Infection (%)	Percentage among total mammals
Bat	<i>Polychromophilus melanipherus</i>	6/19	31.7	1.41
Flying squirrel	-	0/4	0	-
Cat	-	0/1	0	-
Jackal	<i>Babesia canis</i>	1/1	100	0.23
Rabbit	-	0/17	0	-
Rat	-	0/9	0	-
Mice	-	0/38	0	-
Guinae Pig	-	0/8	0	-
Sheep	<i>Anaplasma ovis</i>	19/136	13.2	4.47
	<i>Trypanosoma melophagium</i> (crithidiastage)	1/136	0.73	0.23
Goat	<i>Anaplasma ovis</i>	7/73	9.59	1.64
Cow	<i>Anaplasma marginale</i>	8/53	15.00	1.88
Buffalo	<i>Anaplasma marginale</i>	17/65	26.00	4.00

were found in the blood of mammals, among these four species have been diagnosed. The main criteria for identification of species were based on diagnostic characters described by Garnhum⁶¹.

Family: Babesiidae

Genus: Babesia

Babesia canis: Trophozoites (Fig. 1) were piriform measuring 4-5 μ long or amoeboid i.e 2-4 μ in diameter. Trophozoites generally contained a vacuole. Multiple infections was commonly observed paired forms attached to each other by their narrower ends.

Blood slide of one jackal was observed and found positive. Incidence of infection was 100% (Table 1).

Family: Haemoproteidae

Genus: Polychromophilus

Polychromophilus melanipherus: Youngest form of gametocytes occupied one-sixth of the diameter of the

erythrocyte, they grow in size and tend to assume an oval form with a pigment distributed peripherally. They eventually fill erythrocyte and often still retain a slightly ovoid shape. The envelopes of red blood cell eventually disappear. Mature microgametocyte (Fig. 2) measured about 7-8.34 μ in diameter while the mean diameter of young gametocyte was 2.78 μ .

The diameter of mature gametocyte was obviously larger than non-infected corpuscle. Cytoplasm was very pale or grey in colour, and at least half the body of parasite occupied by a pink staining, spongy mass constituting the nucleus. Pigment granules were black and fairly coarse and were distributed over most of the parasite. Macrogametocyte little larger and measured about 8 μ . Cytoplasm faintly vacuolated and stains bright blue colour, while small nucleus usually lie near edge. Incidence of infection was 31.7% (Table 1).

Family: Anaplasmidae

Genus: Anaplasma

Anaplasma marginale: A spherical granule (Fig. 3) which stained bright red varies in size from 0.1-0.5 μ . It showed no structure, only consist of chromatin without any visible cytoplasm. Situated near the edge of RBC. Multiple infection also found. There is no marked change in the size of infected and normal RBC.

A total of 118 blood samples of cattle (53 cows and 65 buffalos) were collected from the slaughter house of Peshawar city out of which 25 (8 cows and 17 buffalos) were found to be infected with *A. marginale* intensity of infection was 15 and 26% in cows and buffalos, respectively (Table 1).

Highly pathogenic cause a great destruction of red blood cells with resultant anemia, high fever, jaundice and digestive troubles.

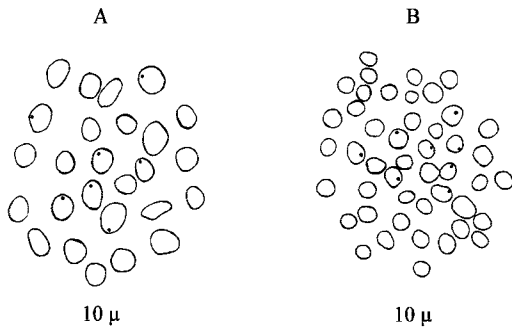


Fig. 3: *Anaplasma ovis*
(a) In Goat's blood (b) In Sheep's blood

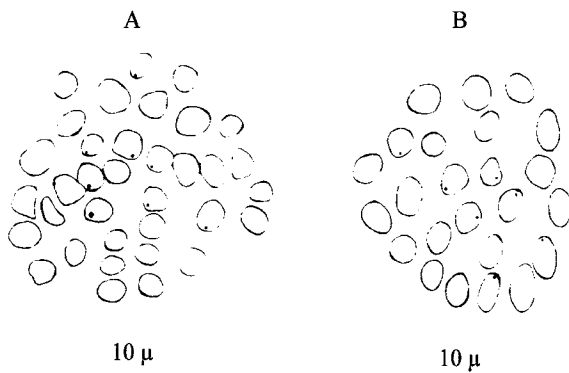


Fig. 4: *Anaplasma marginale*
(a) In Cow's blood (b) In Buffalo's blood

Family: Anaplasmidae

Genus: Anaplasma

Anaplasma ovis: Spherical granules (Fig. 4) stained bright red which distinguished them from jally bodies and basophilic stippling of the red blood cells. Each of these bodies consists of chromatin only, without any visible cytoplasm. These bodies situated near the margin of RBC. No marked difference between the species that occur in sheep (Fig. 3) and cattle (Fig. 4) out of 209 blood samples of sheep and goats 25 were found to be infected with *A. ovis*. Incidence of infection among total mammals was 5.6% while among particular hosts; it was 13.2 and 9.59% in sheep and goats, respectively (Table 1). No marked difference between normal and infected RBC. The size of *A. ovis* ranges from, 0.14-0.20 µ. *A. ovis* is highly pathogenic because a great destruction of RBCs. with resultant anemia, high fever, jaundice and digestive troubles.

Family: Trypanosomatidae

Genus: Trypanosoma

Trypanosoma melophagium (Crithidia stage): Elongated forms (Fig. 5) with short free flagellum, prominent kinetoplast. Range of length was 9-12 µ, width from the

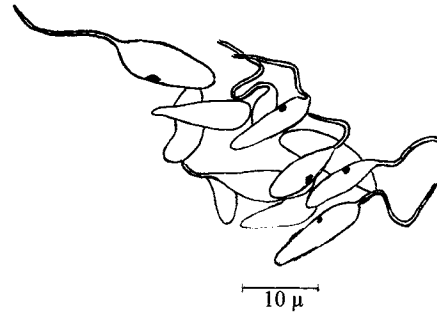


Fig. 5: *Trypanosoma melophagium* crithidia stage

centre was 2-4 µ. The length of the flagella ranges from 9-15 µ. The range of distance between anterior end and kinetoplast was 4-8 µ stages of parasite observed in the blood of sheep was most probably the crithidial stage of the common sp. of Trypanosomes found in sheep from central Asia and Northern India (Fig. 5). Percentage of infection among total mammals was 0.23 and incidence of infection among particular host was 0.37 (Table 1). This stage of parasite was observed in one blood slide of sheep in only one field of x100. The stage was observed in a rosette form. This finding represent the first recorded natural infection with *Polychromophilus melanipherus* in Pakistan.

The blood studies of 424 mammals belonging to different areas of NWFP have been examined. Among those only 59 mammals belonging to 12 species were found positive. *Polychromophilus melanipherus* was observed in six natural bats among the mammals. *Babesia canis* was found in one Jackal. *Anaplasma ovis* observed in 19 sheeps and 7 goats. *Anaplasma marginalae* was found in 8 cows and 17 buffalows while the *Trypanosoma melophagium* crithidia stage observed in only one sheep (Table 1).

Young and mature gametocytes of *Polychromophilus melanipherus* were found in blood slide of bats. These findings represent the first record natural infection with *polychromophilus melanipherus* in Pakistan. *Babesia canis*, *Anaplasma ovis* and *Anaplasma marginalae* were observed only in trophozoite stages. Crithidia stage of Trypanosoma found in the blood of sheep which was most probably the stage of *Trypanosoma melphagium* found in the blood of sheep in central Asia and Northern India.

Natural infection among mammals have been reported by so many researchers from different parts of the world but very little attention was given to natural infection among the mammals in Pakistan. This investigation may be regarded as a pre requiazite of further research work on mammals' infection in Pakistan.

ACKNOWLEDGEMENT

Authors would like to thanks Dr. Rafia Azmat, Associate Professor, Department of Chemistry for her help in writing of the manuscript.

REFERENCES

1. Oslen, O.W., 1962. Animal Parasites. Their Biology and Life Cycle. Burgess Publishing Company, pp: 1-346.
2. Garnham, P.C.C., 1966. Malaria Parasites and Other Haemosporidia. Blackwell Scientific Publication Oxford, pp: 1-114.
3. Garnham, P.C.C., 1967. Malaria in mammals excluding man. Adv. Parasitol., 5: 139-204.
4. Garnham, P.C.C., 1980. Malaria in its Various Vertebrate Hosts. In: Malaria (Ed. Kreier, J.P.). Academic Press, New York, 1: 95-144.
5. Garnham, P.C.C., 1984. The present state of malaria research; on historical survey. Exp. Garnham, P.C.C. Entia, 40: 1305-10.
6. Lepage, G., 1968. Veterinary Parasitology. Oliver and Boyd. Edin Burgh and London, pp: 1-1182
7. Mohiuddin, A., 1970. Some recent advances in our knowledge of Parasites protozoa. Pak. Ass. Adv. Sci., pp: D1-D16 (Presidential Address Read in 21st-22nd Pakistan Science Conference Rayshahi 4-9th Jan., 1970.)
8. Admn, K.M.G., J. Pau and V. Zaman, 1971. Medical and Veterinary Protozoology. Churchill Livingstone Edinburgh and London, pp: 1-199.
9. Hore, C.A., 1972. The Trypanosomes of Mammals. Black well Scientific Publication, pp: 1-749.
10. Levine, N.D. 1973 Protozoan Parasites of Domestic Animals and of Man. Burgers Publicatuion Company. Minneopolis. Minnessota, pp: 1-406.
11. Iliyas, M., and M.A. Anasari, 1982. Community Medicine Sind. Book Bank, Karachi, pp: 330-358.
12. Faust, E.C., P.F. Russell and R.C. Jung, 1984. Crieg and Faust's Clinical Parasitology. Henry Kimpton London, pp: 174-207.
13. Haider, M.J., 1985. Plasmodium malariae infection in Anthropthecus troglodytes in Karachi. Proc. Parasital., 1: 154.
14. Haider, M.J. and F.M. Bilqees, 1986. Studies on Plasmodium infection in some mammals in Karachi. Proc. Parasital., 2: 36-59.
15. Anderson, T.J., 1990. Blood parasites of mammals from Papua New Guinea. J. Ildl. Dis., 26: 291-294.
16. De Rooode, J.C., A.F. Read, B.H.K. Chan and M.J. Mackinnon, 2003. Rodent malaria Parasites suffer from the presence of conspecific clones in three-clone plasmodium chabaudi infection. Rparasitology, 127: 411-418.
17. Reece, S.E., A.B. Duncan, S.A. West and A.F. Read, 2003. Sex ratios in the rodent malaria parasites Plasmodium Chabaudi. Parasitology, 127: 419-425.
18. Borssy, J.J., 1992. Malaria in wild and captive Jakass Penguins. *Sphentscus demersus* along with southern African coast. Ostrich, 63: 10-12.
19. Jones, H.I. and G.R. Shellam, 1999. The Occurrence of blood-inhabiting protozoa in captive and free living penguins. Polar Biol., 12: 5-10.
20. Jones, H.I and S.R. Shellam, 1999 Blood Parasites in penguins and their potential impact on conservation. Marine Ornithol., 27: 181-184.
21. Alkindi, A.Y.A. and I.Y. Mahmoud, 2002. Haematological survey in two species of sea Turtles in the Arabian sea during Nesting season. Pak. J. Biol. Sci., 5: 359-361.
22. Basham, M.A, N.M. ElBagir and M.Es. Barri, 2004. Haematological and histopathological alteration in sodium thiocyanate induced hypothyroid camels (*Camelus dromedaries*). Pak. J. Biol. Sci., 7: 197-200.
23. Talat, R., 2005. Infection of heamatozoan prasites found in birds of NWFP (Pakistan). Pak. J. Biol. Sci., 8: 1-5.